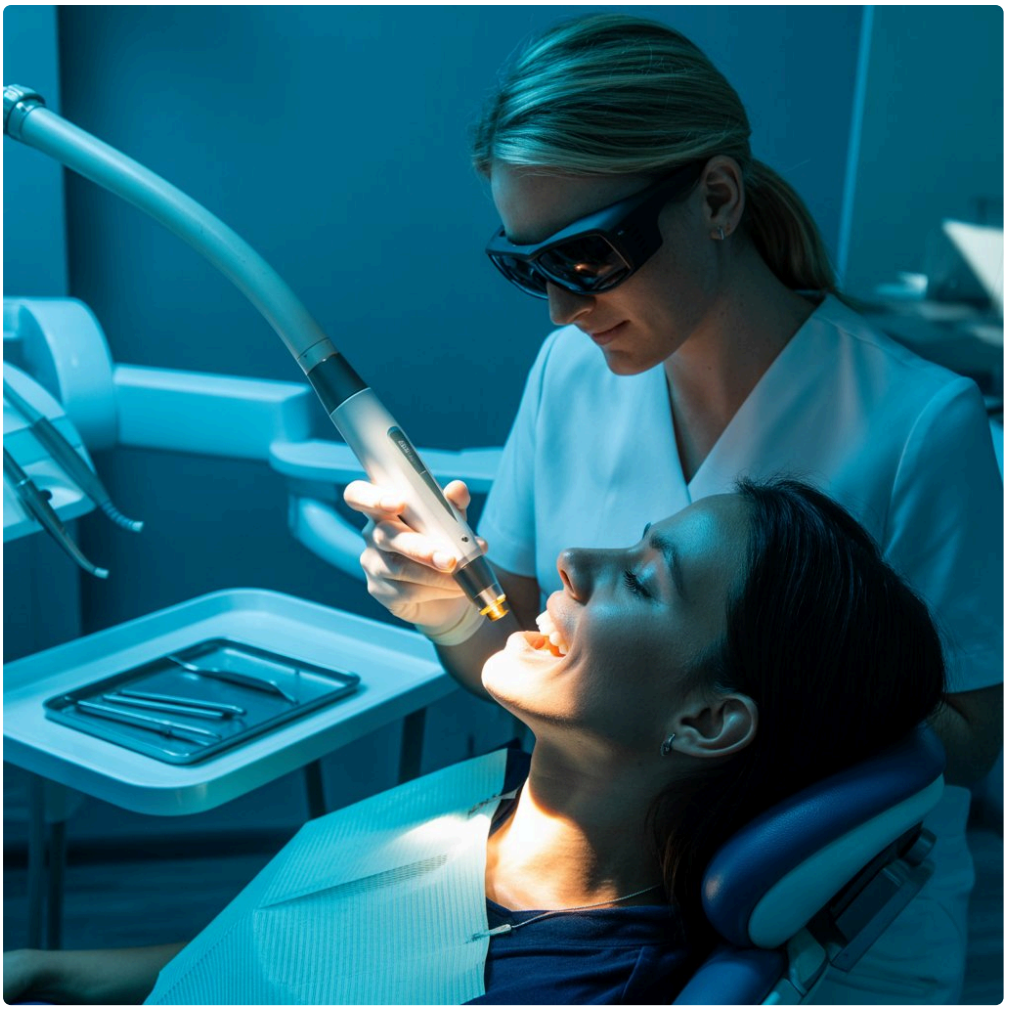

A car accident can leave obvious injuries and hidden ones. People usually notice the bleeding lip, the swollen cheek, or the headache first. Teeth often get attention later, sometimes hours later, sometimes the next day when the shock wears off and a front tooth suddenly looks shorter, loose, or darker than it did before. That delay can matter. Dental trauma does not always announce itself with dramatic pain, and some of the most serious injuries, especially damage to the tooth root, nerve, or supporting bone, can be easy to miss in the first rush of emergency care.

An emergency dentist plays a distinct role after a collision or facial injury. Emergency rooms are essential for life-threatening problems, suspected fractures, uncontrolled bleeding, loss of consciousness, and airway concerns. They are not, however, set up to provide detailed dental trauma treatment in most cases. That gap is where urgent dental care becomes important. A timely dental exam can make the difference between saving a tooth and losing it, between a simple repair and a far more complex restoration months later.

The first priority is not the tooth

When a face strikes a steering wheel, dashboard, airbag, pavement, or another person, dental injuries can happen alongside much more serious trauma. If there is any concern about loss of consciousness, severe neck pain, heavy bleeding, vomiting, confusion, difficulty breathing, or a possible jaw fracture, the emergency room comes first. The same applies if a tooth has been inhaled or there is deep facial laceration that may need sutures.

That can feel frustrating when the front teeth are broken and the patient is panicking about appearance. Still, triage matters. I have seen patients focus intensely on a chipped incisor while ignoring a worsening jaw fracture, and I have seen the opposite, where hospital treatment went well but a completely displaced tooth was never

stored correctly and could not be saved later. The safest approach is to handle urgent medical threats first, then arrange prompt evaluation by an emergency dentist as soon as the patient is medically stable.

What dental trauma looks like after a crash

Not every injured tooth breaks in half. Sometimes the damage is subtle. A tooth may feel “off” when biting, or seem slightly taller than the others. It may shift position by a millimeter or two. The gumline may bleed from one isolated point. The lip may be cut from the inside, and tooth fragments can stay embedded in the soft tissue if no one checks carefully.

A few patterns show up repeatedly after car accidents and sports-style facial injuries. A tooth can chip, crack, loosen, get pushed deeper into the socket, move sideways, or come out completely. The supporting bone around the tooth can fracture even if the crown looks intact. Teeth can also suffer internal injury to the pulp, the soft tissue inside the tooth, without dramatic external damage. Those teeth may not hurt much at first. Weeks later, they may discolor, become sensitive, or develop infection.

Children and adults can both have significant trauma, but the details differ. A child with developing permanent teeth may have treatment decisions shaped by root maturity and future growth. An adult with crowns, veneers, implants, or prior root canals can present a different set of challenges, because existing dental work may mask or complicate the injury pattern.

Timing matters more than many people realize

Dental trauma has a narrow window in some situations. A knocked-out permanent tooth has the best chance of survival if it is replanted quickly, ideally within minutes, though outcomes Emergency Dentist vary based on storage, handling, and the nature of the injury. A displaced tooth may need repositioning and stabilization before swelling and clot formation make the situation more difficult. A cracked tooth with exposed dentin or pulp can become far more painful if it is left unprotected. A cut lip with hidden enamel fragments can heal over those fragments, leading to persistent tenderness and a second procedure later.

Even injuries that do not require minute-by-minute action benefit from same-day or next-day care. When a patient tells me, “It only felt a little sore at first, so I waited a week,” the exam often reveals movement, bite trauma, nerve changes, or infection risk that would have been simpler to manage earlier.

What to do right away

The moments after a crash are chaotic, especially if airbags deployed or the person is dazed. Clear steps help.

1. Get medical help first if there is heavy bleeding, possible head or neck injury, trouble breathing, severe jaw pain, or loss of consciousness.
2. If a permanent tooth is knocked out, pick it up by the crown, not the root, and place it back in the socket if possible. If not, store it in milk or saliva and seek urgent dental care immediately.
3. Apply gentle pressure with clean gauze for oral bleeding, and use a cold compress on the outside of the face to reduce swelling.
4. Save broken tooth pieces if you can find them, because they are sometimes useful for repair.
5. Do not ignore a “minor” tooth injury if the bite feels different, the tooth is loose, or the gumline is bleeding around one tooth.

Those steps are practical, but they do not replace an exam. People often assume that if they can close their teeth together, the jaw is fine, or if the tooth is still in place, it is safe to wait. Both assumptions can be wrong.

The difference between a chip and a true emergency

A small edge chip with no pain is not the same as a tooth that has shifted in the socket or one with a visible red spot in the center where the pulp is exposed. The challenge is that the average person is not expected to know the difference. Even clinicians outside dentistry can miss it if the mouth is not their routine focus.

A superficial chip usually affects only enamel. It may feel sharp, look uneven, and be aesthetically upsetting, but it is often less urgent from a biological standpoint. A deeper fracture that exposes the inner tooth structure can lead to sensitivity, bacterial contamination, and nerve damage. A vertical crack from impact can be much harder to see and can threaten the long-term prognosis of the tooth even if the crown appears mostly intact.

Looseness is another warning sign. A tooth that wiggles after trauma should not be dismissed as “just bruised.” In some cases the periodontal ligament, the microscopic fibers that anchor the tooth, has been severely injured. In others, the surrounding bone is involved. Stabilization with a splint for a short period may improve healing. Waiting too long can complicate alignment and recovery.

Why pain is an unreliable guide

One of the more counterintuitive parts of dental trauma is that severe damage can be surprisingly painless at first. Adrenaline after a crash can blunt pain. Nerve injury can alter sensation. A tooth that has lost blood supply may initially feel dull rather than acutely painful. Meanwhile, a relatively small enamel fracture can feel dramatic because the edge cuts the tongue.

That is why experienced emergency dentists rely on more than symptoms. The exam usually includes careful visual inspection, bite assessment, mobility testing, soft tissue evaluation, and dental X-rays. Sometimes additional imaging is needed if root fracture or jaw fracture is suspected. Photographs can also help document changes over time, which matters because traumatized teeth may evolve in the days and weeks after the injury.

What an emergency dentist is actually looking for

The emergency appointment after a facial injury is not just about patching what is obvious. The dentist is trying to answer a series of practical questions. Is the tooth restorable. Is the nerve likely to survive. Has the tooth moved. Is there damage to the root or socket. Are there fragments inside the lip or cheek. Is the bite now causing repeated trauma. Does the patient need immediate stabilization, protective covering, sutures, antibiotics in select cases, or referral to an oral surgeon or endodontist.

Sometimes the first visit is about controlling the situation rather than completing the final repair. For example, a badly fractured front tooth may need a protective temporary build-up and follow-up monitoring before anyone decides whether root canal treatment is necessary. A luxated tooth, meaning one that has been displaced, may need repositioning and splinting now, then reassessment later for vitality. A patient with several injured teeth may require staged care because not every answer is available on day one.

That uncertainty can be difficult for patients. They often want a yes or no answer immediately, especially when the tooth is visible and the accident was already emotionally expensive. Good trauma care involves some patience. Teeth reveal their true prognosis over time.

The hidden injuries people miss

The mouth is full of clues after impact, and some of the most important ones are easy to overlook. A lip laceration from hitting the teeth can contain tiny enamel shards. If those are not found, the lip may remain firm or tender long after the surface looks healed. A patient may think the discomfort is just scar tissue when it is actually a fragment that should have been removed.

Bite changes matter too. If the teeth no longer come together the same way, there may be tooth intrusion, jaw injury, or swelling altering the occlusion. One patient may describe it as “my front teeth hit first now.” Another says, “It feels like one tooth is sticking out.” Those details can guide diagnosis.

Color changes are also important. A tooth that turns gray, yellow, or pink after trauma should be evaluated, even if there is no active pain. Pink can suggest internal bleeding or resorption in certain settings. Gray may indicate loss of vitality. Yellow can reflect calcific changes as the pulp responds to injury. None of those color changes should be diagnosed by appearance alone, but they should not be ignored.

Car accidents create a particular pattern of dental problems

Not all facial injuries are the same. Car accidents often involve high force, sudden deceleration, and multiple contact points. Airbags reduce many severe injuries, but they do not prevent every oral injury. In fact, the combination of impact, restraint forces, and involuntary jaw clenching can leave patients with a mix of broken teeth, bruised ligaments, sore jaw joints, and soft tissue trauma.

Seatbelt use changes the overall injury profile, but restrained occupants can still strike the airbag or steering wheel depending on position, speed, and timing. Children in car seats have different vectors of force than adults. Passengers can injure teeth on phones, cups, or other objects in the car, not just the vehicle interior. I have seen cracked incisors from water bottles, fractured molars from impact-related clenching, and lip injuries from orthodontic brackets driven into the tissue.

That variety is one reason a broad dental exam matters. The obvious front tooth is not always the only issue. Back teeth may crack under forceful collision of the jaws. Existing fillings may fracture. The temporomandibular joints may become painful or click weeks later. A thorough emergency dentist will look beyond the tooth that first caught the patient’s eye.

If a tooth is knocked out, every minute helps

A knocked-out permanent tooth is one of the clearest dental emergencies. The biology is straightforward. Cells on the root surface begin to die once the tooth dries out. The better those cells survive, the better the chances that the tooth can reattach functionally after replantation.

If the tooth is dirty, it should be rinsed briefly with milk or saline if available. Scrubbing, scraping, or wrapping it in tissue causes damage. Holding it by the crown is critical because the root surface is delicate. Placing it back into the socket is best when the person is alert and cooperative and there is no aspiration risk. If replantation is not feasible, cold milk is a practical storage medium that many people can access quickly. Saliva may be used if needed, though it is not ideal for every circumstance. Water is better than letting the tooth dry, but plain water is not the first choice.

Primary teeth, or baby teeth, are different. They are generally not replanted because of the risk of harming the developing permanent tooth. That distinction is one reason parents should call promptly rather than rely on internet guesses.

Treatment can be simple, or surprisingly involved

Patients sometimes assume emergency dental care means one quick repair. Sometimes it does. A minor chip may need smoothing or bonding. A displaced tooth may be repositioned and splinted in one visit. But higher-force trauma often unfolds over several stages.

The short-term goal is to preserve tissue, control pain, prevent contamination, and stabilize what can be saved. The medium-term goal is to monitor healing and intervene if the pulp dies, infection appears, or the tooth changes position. The long-term goal is to restore function and appearance with the least invasive option that will last.

That sequence may include composite bonding, splinting, root canal treatment, crown placement, gum contouring, or replacement options if the tooth cannot be saved. Young patients may need temporary strategies while growth continues. Adults with severe fracture or root damage may move toward implant planning, though not always immediately. Bone and soft tissue conditions after trauma can influence timing.

Soft tissue injuries deserve more respect than they get

People often focus on the teeth because they are visible and symbolic. The lip, cheek, and gums deserve equal attention. Lacerations inside the mouth bleed heavily because oral tissues are well supplied with blood. They also swell fast. A cut gumline around a tooth can signal more than a surface injury, especially if it corresponds with tooth mobility or displacement.

Facial wounds also affect dental treatment choices. A splint or temporary restoration must coexist with swelling, tenderness, and the patient's ability to maintain oral hygiene. This is not a small detail. Plaque accumulates easily around traumatized teeth and splints, and poor hygiene can undermine healing.

For that reason, patients often leave with very specific instructions about rinsing, brushing carefully, choosing softer foods, and returning for follow-up even if they feel better.

Follow-up is part of emergency care, not an optional extra

Traumatized teeth can change course weeks or months after the accident. A tooth that tests normal on the first day may fail later. A splinted tooth may heal well, or it may develop root resorption. A front tooth may look stable but darken gradually. That is why one visit is rarely the entire story.

A reasonable follow-up plan often includes short-term review to check mobility, bite, and soft tissue healing, then later visits to monitor vitality and radiographic changes. The exact schedule depends on the injury, the patient's age, and whether the root is fully developed. This is less dramatic than the emergency itself, but it is where many teeth are ultimately saved or lost.

I have seen patients disappear after the acute visit because the tooth "seemed fine," only to return months later with swelling above the root and much narrower treatment options. Monitoring is not overcautious. It is standard good care after trauma.

Insurance, documentation, and practical realities

Car accident cases often involve overlapping medical and dental issues, and patients are understandably overwhelmed. Good records matter. Photographs, radiographs, notes *Emergency Dentist* on mobility and soft tissue injuries, and timelines of symptoms can all be important for both treatment and insurance purposes. If the

injury relates to a motor vehicle claim, documentation from the emergency dentist may help establish the extent and timing of the dental damage.

That said, treatment should not be delayed while paperwork gets sorted out. A dislodged tooth does not improve because an adjuster has not called back. Most emergency dental offices understand this and can at least begin essential care while the financial side is being clarified.

When to call immediately, even if the hospital already saw you

There is a common misunderstanding that once a patient has been discharged from the emergency room, everything urgent has been handled. For dental trauma, that is often not true. Call an emergency dentist right away if any of the following is happening:

- A tooth is knocked out, loose, pushed out of place, or suddenly feels taller when you bite.
- A tooth is broken enough to expose a yellow or red inner layer, or it becomes sharply sensitive to air or water.
- The lip, cheek, or gum was cut by the teeth and still feels firm or tender, suggesting a trapped fragment.
- The bite no longer fits together normally, or the jaw cannot close comfortably.
- Pain, swelling, or tooth discoloration appears in the hours or days after the injury.

Those signs justify prompt evaluation even if the patient was already assessed medically and sent home.

The goal is not just appearance

Front tooth injuries after a crash are emotionally charged. People worry about work, school photos, weddings, court dates, and simply being seen in public. Appearance matters, and any dentist who treats trauma knows that. Still, the real goal is broader. The aim is to preserve living tissue when possible, restore function, protect the bite, prevent infection, and set up the most durable long-term result.

Sometimes that means a fast cosmetic repair on day one. Sometimes it means a temporary patch and a difficult conversation about prognosis. The professional judgment lies in knowing which is which. A beautiful repair on an unsound foundation is not a good result. Neither is excessive treatment on a tooth that could have healed with conservative care.

That balance is what a skilled emergency dentist brings after a car accident or facial injury. In the first hours, the work is urgent and practical. In the weeks that follow, it becomes careful and strategic. Both phases matter, and both can have lasting effects on whether the patient keeps their natural teeth, their comfort, and their confidence.

Vitality Dental
1220 Coit Rd # 106, Plano, TX 75075, United States

+1 972-645-4100

FAQ About Emergency Dentist

What counts as a dental emergency?

A knocked-out tooth, significant mouth injury, severe tooth pain, or painful swelling warrants prompt evaluation. Call your dentist and describe your symptoms so the office can advise you on how urgently you need care.

What should I do if I knock out a permanent tooth?

Call a dentist immediately. Handle the tooth by the crown, avoid touching the root, and keep it moist. If you cannot put it back into the socket easily, transport it in milk or a tooth-preservation solution. Bring it with you to the appointment.

Should I go to the emergency room for a dental emergency?

Seek emergency medical care right away if you have trouble breathing or swallowing, uncontrolled bleeding, or a serious facial injury. For an isolated tooth injury or toothache without those symptoms, call a dentist promptly for guidance.